

Activation–deactivation rapid palatal expansion and reverse headgear in Class III cases

Devrim Isci, Tamer Turk and Selma Elekdag-Turk

Department of Orthodontics, Faculty of Dentistry, University of Ondokuz Mayıs, Samsun, Turkey

Correspondence to: Dr Tamer Turk, Department of Orthodontics, Faculty of Dentistry, University of Ondokuz Mayıs, Kurupelit 55139, Samsun, Turkey. E-mail: turkset@superonline.com

SUMMARY The aim of this study was to evaluate and compare the dentofacial effects of 1 week rapid palatal expansion (RPE) and activation–deactivation (A/D) RPE protocols with reverse headgear (RH).

Two groups, each containing 15 subjects, were included in this study. In the RPE group (seven males and eight females, 11.94 ± 1.62 years), Hyrax screws were activated every 12 hours for 1 week. At the end of this period, RPE was stopped and the patients were instructed to wear the RH. In the A/D-RPE group (seven males and eight females, 11.34 ± 1.81 years), the screws were activated every 12 hours for 1 week. Subsequently, the screws were deactivated every 12 hours for 1 week followed by activation and deactivation for the following 2 weeks. After this protocol, the patients were instructed to use the RH. A total force of 700 g was applied to both groups for 16–18 hours/day for the first 3 months, for 12 hours/day for the second 3 months, and for 6 hours/day for the second 6 months. Lateral cephalometric films were taken before treatment (T1) and at the end of the first (T2) and second (T3) 6 months to evaluate the dentofacial changes. Intragroup differences of each landmark at T2–T1, T3–T2, and T3–T1 were analysed with a paired *t*-test ($P < 0.016$), and intergroup differences were compared with an independent *t*-test ($P < 0.05$).

Anterior movement of point A (4.13 mm) for the A/D-RPE group was approximately twice of the RPE group (2.33 mm; $P < 0.001$). Backward movement of the mandible showed no significant difference between the groups. Anterior face height increases did not demonstrate significant differences between the groups. The pronounced anterior movement of point A demonstrates that the A/D-RPE procedure positively affects maxillary protraction.

Introduction

Cephalometric analysis may indicate that a skeletal Class III malocclusion may be due primarily to mandibular protrusion, maxillary retrusion, or a combination of the two (Dellinger, 1973; Mermigos *et al.*, 1990).

The contribution of maxillary retrusion to a Class III malocclusion has been evaluated in several studies (Sanborn, 1955; Jacobson *et al.*, 1974; Ellis and McNamara, 1984; Guyer *et al.*, 1986; Williams and Andersen, 1986). The percentage of maxillary retrusion in Class III subjects with a normal mandible was reported as 19.5 per cent (Ellis and McNamara, 1984), 25 per cent (Guyer *et al.*, 1986), 26 per cent (Jacobson *et al.*, 1974), 33 per cent (Sanborn, 1955), and 37 per cent (Williams and Andersen, 1986). This undeniable contribution of maxillary retrusion to Class III malocclusions led to the introduction of treatment modalities for maxillary retrusion. The orthopaedic facemask was introduced for maxillary protraction with a forehead and chin support (McNamara and Brudon, 1993).

The result of several orthopaedic facemask studies revealed a significant amount of maxillary forward movement without rapid palatal expansion (RPE; Mermigos *et al.*, 1990; Kiliçoglu and Kirliç, 1998; Suda *et al.*, 2000; Göyenc and Ersoy, 2004; Kajiya *et al.*, 2004). Despite

the successful results of facemask therapy without RPE, maxillary expansion has been recommended as a routine part of Class III correction even in the absence of maxillary constriction or crowding (Turley, 1996; Baccetti *et al.*, 1998; Ngan *et al.*, 1998; Saadia and Torres, 2000). In the absence of maxillary constriction, the rapid palatal expander is still usually activated for 7–10 days, with different daily activations (Turley, 1996; Baccetti *et al.*, 1998; Ngan *et al.*, 1998; Saadia and Torres, 2000). In instances in which maxillary expansion is necessary, activation of the maxillary expander depends on the amount of constriction (Baccetti *et al.*, 1998; Saadia and Torres, 2000). The main benefits of palatal expansion include expansion of a narrow maxilla and loosening or activation of the circum-maxillary sutures, and initiating a downward and forward movement of the maxillary complex (Turley, 2007).

A repetitive weekly protocol of alternate rapid maxillary expansion and constriction (Alt-RAMEC) was presented by Liou (2005a) to disarticulate the circum-maxillary sutures. With this protocol, the maxilla is expanded 1 mm/day for 1 week, then constricted 1 mm/day for the next week with a two-hinged rapid maxillary expander. This procedure can be repeated for 7–9 weeks to disarticulate the maxilla (Liou, 2005a,b; Liou and Tsai, 2005). The rationale is similar to

that of simple tooth extraction, in which the tooth is rocked buccally and lingually until it is 'loosened' from the alveolar socket (Liou, 2005a,b; Liou and Tsai, 2005). Thus, the maxilla is disarticulated without being over-expanded (Liou, 2005b; Liou and Tsai, 2005).

Intraoral maxillary protraction springs were used for the protraction of the maxilla in the above-mentioned treatment protocol (Liou, 2005a,b; Liou and Tsai, 2005). An average anterior movement of point A of 5.8 mm was observed with 9 weeks of Alt-RAMEC in cleft patients (Liou and Tsai, 2005); whereas, 2.6 mm anterior movement of point A was reported with RPE for 1 week (Liou and Tsai, 2005). This difference was attributed to the Alt-RAMEC, which opens the circum-maxillary sutures more extensively than 1 week of RPE. To test this assumption, Wang *et al.* (2009), in an experimental study on cats, quantitatively studied the extent of circum-maxillary suture opening after 1 week of RPE and after 5 weeks of Alt-RAMEC. The results supported the assumption that Alt-RAMEC opens the circum-maxillary sutures more extensively than RPE (Wang *et al.*, 2009).

The aim of this study was to evaluate and compare the dentofacial effects of 1 week of RPE and activation–deactivation A/D-RPE protocols with reverse headgear (RH) application.

Subjects and methods

Case selection

Ethical approval was obtained from the Medical Faculty Ethics Committee of the University of Ondokuz Mayıs (EK: 135) and all patients and their guardians consented to participate in this study after receiving verbal and written explanations.

This prospective study comprised 30 patients (14 females and 16 males) with an Angle Class III molar relationship, negative overjet, erupted upper first premolars, a concave profile, and a Class III skeletal pattern (ANB less than 0 degrees) due to a retrusive maxilla with or without mandibular protrusion. None of the patients had any craniofacial anomalies (e.g. cleft lip and palate). Two groups, each containing seven females and eight males, were composed.

Appliances for Class III correction

The Hyrax RPE appliance was constructed using bands on the posterior teeth. Bands were fitted on the maxillary first premolars and permanent first molars. A jack screw (A0620-11; Leone SpA, Firenze, Italy) was placed at the midline; the anterior and posterior extensions were soldered to premolar and molar bands, respectively. In addition, a lingual wire was soldered from the premolar band to the molar band for rigidity. A 0.045 inch wire was soldered bilaterally to the buccal aspects of the molar bands and extended anteriorly to the canines for elastic traction.

In the RPE group (average chronological age 11.94 ± 1.62 years), the screw was activated twice daily (0.20 mm

per turn) for 1 week. The screw was opened for 2.8 mm. At the end of this period, expansion was stopped and the patients were instructed to wear the RH.

In the A/D-RPE group (average chronological age 11.34 ± 1.81 years), the screw was activated twice daily (0.20 mm per turn) for 1 week. Subsequently, the screw was deactivated twice daily (0.20 mm per turn) for 1 week. At the end of each activation or deactivation period, the patients were examined to control opening or closing of the screw. This activation and deactivation protocol was repeated once more. After this activation and deactivation protocol, the patients were instructed to wear the RH (Figure 1).

In both groups, a Delaire type RH was used. The protraction elastics were attached to the hooks mesial to the maxillary canines with a downward and forward pull of 20 degrees to the occlusal plane. During the first 3 month period, a total force of 700 g was applied in both groups (16–18 hours/day). For the second 3 month period, the RH

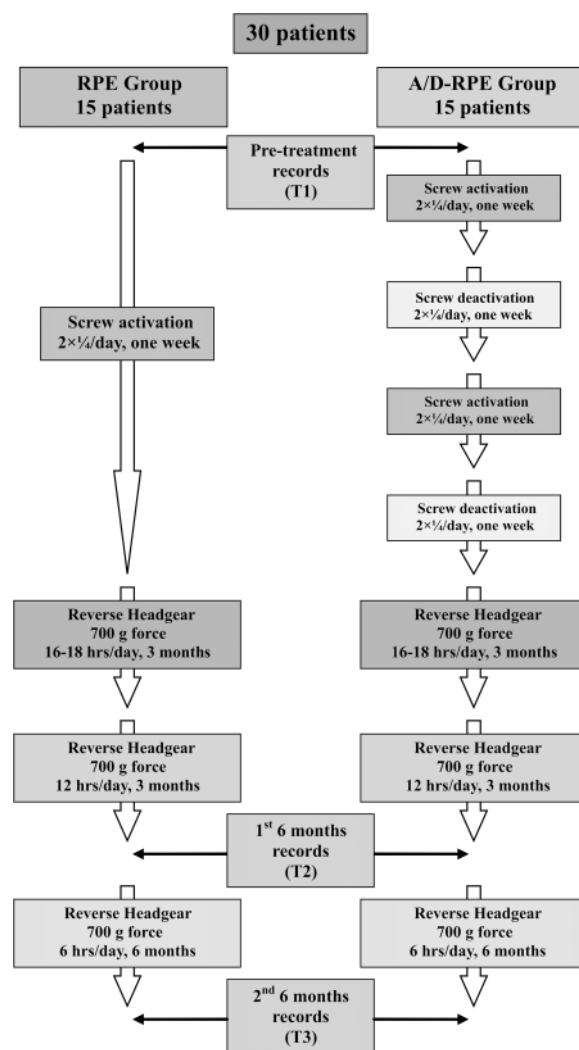


Figure 1 Treatment protocol for the rapid palatal expansion (RPE) and the activation/deactivation-rapid palatal expansion (A/D-RPE) groups.

was used for 12 hours/day and for the following 6 months for 6 hours/day (nighttime) both with the same force level.

Cephalometric analysis

For both groups, cephalometric films were taken before treatment (T1) and at the end of the first (T2) and second (T3) 6 month treatment periods.

Lateral cephalometric tracings at T1, T2, and T3 were superimposed on the cranial base. The changes in the cephalometric landmarks in the sagittal plane between the two tracings were measured by a Cartesian co-ordinate system. A horizontal reference line (SN) was used as the x -axis. A perpendicular line (VRL), passing through sella to the x -axis, served as the y -axis. Thirty-three

cephalometric variables (14 skeletal, 10 dental, and nine soft tissue) were used to evaluate changes of the dentofacial structures and the soft tissue profile (Figure 2). All cephalometric tracings and measurements were performed by one author (DI).

Statistical analysis

Intragroup differences of each landmark at T2–T1, T3–T2, and T3–T1 were analysed with a paired t -test ($P < 0.016$), and intergroup differences were compared with an independent t -test ($P < 0.05$). Four weeks after the first measurements, tracing and calculations of the cephalograms of 15 subjects were undertaken by the same author. Intraclass correlation coefficients were found to be within 0.91–0.98.

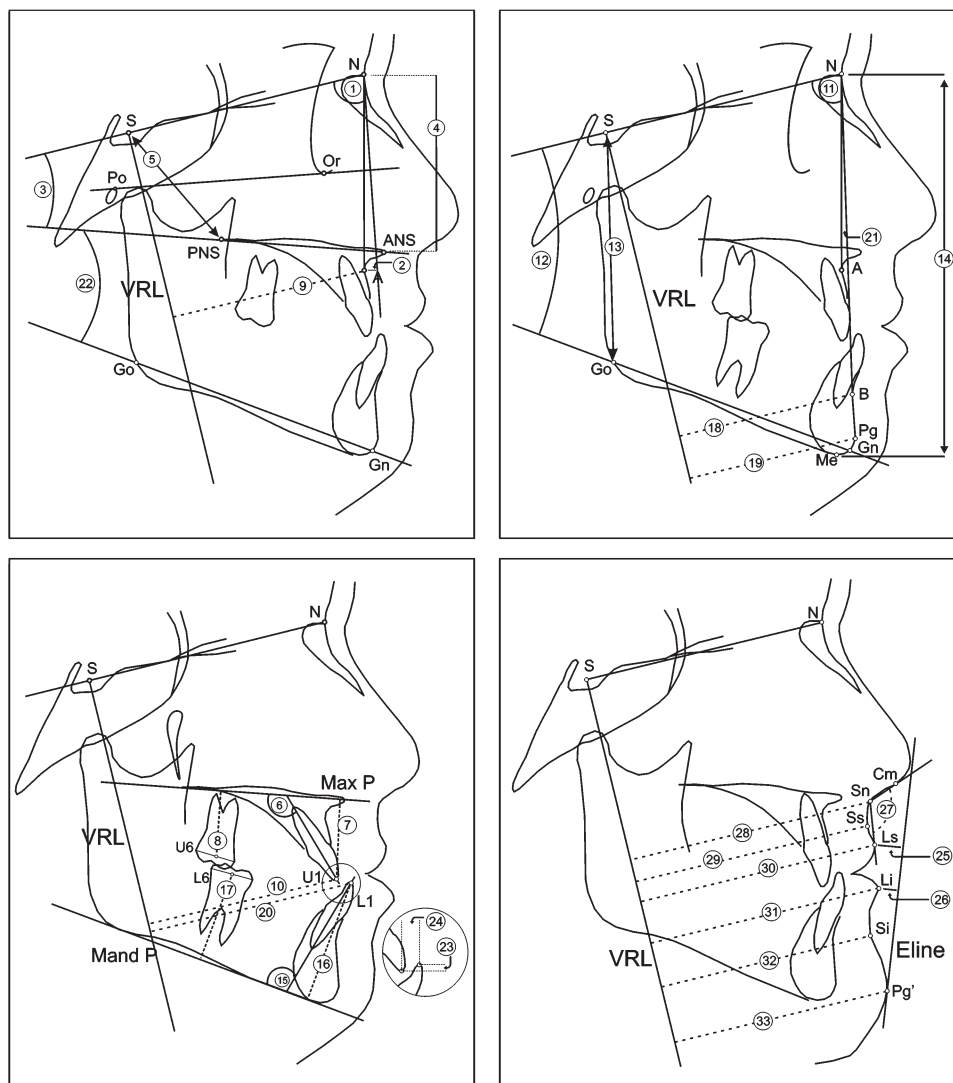


Figure 2 Cephalometric variables (14 skeletal, 10 dental, and nine soft tissue) used to evaluate changes of the dentofacial structures and the soft tissue profile: (1) SNA, (2) $FN^{\perp}N-A$, (3) SN/ANS–PNS, (4) N–ANS, (5) S–PNS, (6) U1/ANS–PNS, (7) U1–MaxP, (8) U6–MaxP, (9) VRL–A, (10) VRL–U1, (11) SNB, (12) SN/Go–Gn, (13) S–Go, (14) N–Me, (15) L1/MandP, (16) L1–MandP, (17) L6–MandP, (18) VRL–B, (19) VRL–Pg, (20) VRL–L1, (21) ANB, (22) ANS–PNS/Go–Gn, (23) Overbite, (24) Overjet, (25) Ls–E line, (26) Li–E line, (27) Nasolabial angle, (28) VRL–Sn, (29) VRL–Ss, (30) VRL–Ls, (31) VRL–Li, (32) VRL–Si, (33) VRL–Pg'.

Results

Table 1 shows the comparisons of the mean initial angular and linear measurements for the dentofacial structures and the soft tissue profile between the RPE and A/D-RPE groups. No statistically significant difference was observed between the two groups.

T1 to T2 changes

At the end of the first 6 months, anterior movement of point A (VLR–A, FH[⊥]N–A) and posterior movement of points B

Table 1 Comparison of initial cephalometric values between the rapid palatal expansion (RPE) and the activation/deactivation-rapid palatal expansion (A/D-RPE) groups (independent *t*-test).

Variables		RPE		A/D-RPE		<i>t</i> -test
		Mean	SD	Mean	SD	
Maxillary skeletal and dental						
1	SNA (°)	75.33	3.37	76.77	4.13	ns
2	FH [⊥] N–A (mm)	−4.20	3.41	−4.60	3.97	ns
3	SN/ANS–PNS (°)	12.30	3.50	11.67	4.67	ns
4	N–ANS (mm)	52.47	3.62	52.63	4.36	ns
5	S–PNS (mm)	42.63	3.86	43.90	4.16	ns
6	U1/ANS–PNS (°)	108.00	19.25	109.60	15.78	ns
7	U1–MaxP (mm)	26.80	1.49	26.33	4.43	ns
8	U6–MaxP (mm)	17.90	2.41	17.20	2.91	ns
9	VRL–A (mm)	51.83	3.28	51.60	3.50	ns
10	VRL–U1 (mm)	51.47	4.97	50.50	5.22	ns
Mandibular skeletal and dental						
11	SNB (°)	78.17	3.05	79.80	4.23	ns
12	SN/Go–Gn (°)	37.63	4.42	36.53	4.79	ns
13	S–Go (mm)	69.60	4.23	70.27	5.48	ns
14	N–Me (mm)	115.57	5.34	113.90	11.03	ns
15	L1/MandP (°)	81.80	7.14	79.23	9.30	ns
16	L1–MandP (mm)	38.20	2.53	37.20	3.60	ns
17	L6–MandP (mm)	25.20	1.91	24.27	2.92	ns
18	VRL–B (mm)	46.00	5.63	47.60	6.94	ns
19	VRL–Pg (mm)	44.93	6.16	46.40	7.79	ns
20	VRL–L1 (mm)	54.87	4.98	53.90	4.72	ns
Intermaxillary						
21	ANB (°)	−2.83	2.22	−3.03	2.57	ns
22	ANS–PNS/Go–Gn (°)	25.30	4.36	25.07	5.68	ns
23	Overbite (mm)	2.07	1.45	2.67	2.20	ns
24	Overjet (mm)	−3.40	1.66	−3.40	1.47	ns
Soft tissue						
25	Ls–E line (mm)	−5.17	2.51	−6.03	2.75	ns
26	Li–E line (mm)	−0.53	2.56	−1.33	2.64	ns
27	Nasolabial angle (°)	102.07	12.19	109.13	15.90	ns
28	VRL–Sn (mm)	68.73	4.23	67.33	3.75	ns
29	VRL–Ss (A'; mm)	66.37	4.34	65.33	4.36	ns
30	VRL–Ls (mm)	68.03	4.70	66.83	5.08	ns
31	VRL–Li (mm)	66.73	5.04	65.97	5.29	ns
32	VRL–Si (B'; mm)	57.70	5.72	59.40	5.93	ns
33	VRL–Pg' (mm)	56.37	6.72	58.27	7.52	ns

ns, non-significant.

and Pg (VRL–B, VRL–Pg) were significant for both groups (Table 2). The increase of SNA, decrease of SNB, and increase of ANB angles were significant for both groups.

Total (N–Me) and upper anterior (N–ANS) face heights increased significantly during the first 6 months for both groups. Furthermore, maxillary posterior height (S–PNS) and posterior face height (S–Go) demonstrated a significant increase for both groups. Both groups presented significant increases for SN/Go–Gn and ANS–PNS/Go–Gn angles. However, the maxillary plane angle (SN/ANS–PNS) showed a significant decrease, but only for the A/D-RPE group.

Anterior movement of the upper incisors (VRL–U1) and posterior movement of the lower incisors (VRL–L1) were significant for both groups. Furthermore, vertical movement of the upper incisors (U1–MaxP) and first molars (U6–MaxP) and lower incisors (L1–MandP) and first molars (L6–MandP) were significant. The decrease of overbite and increase of overjet were significant for both groups.

At the end of the first 6 months, anterior movement of the upper lip (Ls–E line, VRL–Sn, VRL–Ss, and VRL–Ls) was significant for the RPE and A/D-RPE groups. Soft tissue B (VRL–Si) and Pg (VRL–Pg') points moved posteriorly for both groups.

Anterior movement of point A and the increase of SNA angle presented significant differences between the groups. Anterior movement of the upper incisors in the A/D-RPE group was significantly greater than in the RPE group.

The increase of ANB angle and overjet was significantly greater in the A/D-RPE group. Furthermore, anterior movement of the upper lip (Ls–E line, VRL–Ss, and VRL–Ls) showed a significant difference between the groups.

T2 to T3 changes

At the end of the second 6 months, total and upper anterior face heights and maxillary posterior height increased significantly in both groups (Table 3). Vertical movement of the upper incisors, anterior movement of the lower incisors, and anterior movement of Sn, Ss, Ls, and Pg soft tissue points were significant for both groups.

In the RPE group, vertical movement of the upper first molars, the increase of posterior face height, the vertical movement of the lower incisors and the first molars, and the anterior movement of soft tissue point B were statistically significant.

In the A/D-RPE group, anterior movement of point A and the upper incisors, the increase of lower incisor inclination (L1/MandP), anterior movement of the lower lip, and increase of overbite were significant.

Anterior movement of points A and Sn demonstrated significant differences between the groups.

T1 to T3 changes

At the end of 12 months, anterior movement of point A and posterior movement of points B and Pg were significant for

Table 2 Significance of mean changes during first 6 months (T2–T1) for the rapid palatal expansion (RPE) and the activation/deactivation-rapid palatal expansion (A/D-RPE) groups (paired *t*-test) and comparison of these changes between the two groups (independent *t*-test).

Variables		RPE			A/D-RPE			<i>P</i> ***
		Mean	SD	<i>P</i> *	Mean	SD	<i>P</i> *	
Maxillary skeletal and dental								
1	SNA (°)	1.87	1.01	***	3.10	1.24	***	**
2	FH–N–A (mm)	1.90	1.23	***	2.60	1.61	***	ns
3	SN/ANS–PNS (°)	−0.70	1.13	ns	−1.23	1.22	**	ns
4	N–ANS (mm)	1.13	0.88	***	1.30	0.86	***	ns
5	S–PNS (mm)	1.87	1.11	***	2.57	1.02	***	ns
6	U1/ANS–PNS (°)	1.53	3.54	ns	1.13	3.44	ns	ns
7	U1–MaxP (mm)	0.83	0.75	**	0.80	0.92	*	ns
8	U6–MaxP (mm)	2.97	1.49	***	3.37	1.08	***	ns
9	VRL–A (mm)	2.03	1.30	***	3.20	1.21	***	*
10	VRL–U1 (mm)	2.90	1.98	***	5.27	1.44	***	***
Mandibular skeletal and dental								
11	SNB (°)	−1.43	0.78	***	−1.60	0.81	***	ns
12	SN/Go–Gn (°)	2.33	1.85	***	2.13	2.10	**	ns
13	S–Go (mm)	1.37	1.52	*	2.37	1.53	***	ns
14	N–Me (mm)	4.07	1.88	***	5.13	1.77	***	ns
15	L1/MandP (°)	−0.23	3.36	ns	−1.77	3.40	ns	ns
16	L1–MandP (mm)	1.00	0.65	***	1.43	0.82	***	ns
17	L6–MandP (mm)	0.97	1.14	*	1.57	1.94	*	ns
18	VRL–B (mm)	−2.47	2.35	**	−3.03	2.33	***	ns
19	VRL–Pg (mm)	−2.57	2.15	**	−3.23	2.41	***	ns
20	VRL–L1 (mm)	−2.17	1.85	**	−2.27	1.49	***	ns
Intermaxillary								
21	ANB (°)	3.30	1.33	***	4.70	1.49	***	**
22	ANS–PNS/Go–Gn (°)	2.37	1.68	***	3.23	1.91	***	ns
23	Overbite (mm)	−1.77	1.80	**	−1.77	2.04	*	ns
24	Overjet (mm)	5.07	2.62	***	7.53	1.54	***	***
Soft tissue								
25	Ls–E line (mm)	1.87	2.44	*	3.50	1.83	***	*
26	Li–E line (mm)	−0.27	1.36	ns	−0.03	1.47	ns	ns
27	Nasolabial angle (°)	1.13	6.19	ns	−0.33	7.94	ns	ns
28	VRL–Sn (mm)	1.70	1.67	**	3.23	2.79	**	ns
29	VRL–Ss (A') (mm)	1.73	1.99	*	3.63	1.54	***	**
30	VRL–Ls (mm)	1.63	2.22	*	3.50	1.48	***	**
31	VRL–Li (mm)	−1.33	2.78	ns	−0.73	1.41	ns	ns
32	VRL–Si (B') (mm)	−2.13	2.17	**	−1.83	2.27	*	ns
33	VRL–Pg' (mm)	−2.93	2.31	***	−2.97	2.33	***	ns

ns, non-significant; minus sign values indicate a decrease.

*Intragroup comparison, paired *t*-test **P* < 0.016, ***P* < 0.0033, ****P* < 0.00033**Intercomparison, independent *t*-test **P* < 0.05, ***P* < 0.01, ****P* < 0.001.

both groups (Table 4). The increase of SNA, decrease of SNB, and increase of ANB angles were significant for both groups.

Total and upper anterior face, maxillary posterior, and posterior face heights demonstrated significant increases for both groups. Both groups presented significant increases for SN/Go–Gn and ANS–PNS/Go–Gn angles. However, the maxillary plane angle showed a significant decrease but only for the A/D-RPE group.

Anterior movement of the upper incisors and vertical movement of the upper incisors and first molars were significant for both groups. Vertical movement of the lower

incisors and lower first molars were significant. Overjet increase was significant for both groups. Posterior movement of the lower incisors and the decrease of overbite were significant in the RPE group only.

Anterior movement of the upper lip was significant for both groups. In the RPE group, posterior movement of soft tissue Pg point was significant.

Comparison of the mean changes between the RPE and A/D-RPE groups showed that the anterior movement of point A, the increase of SNA angle, the anterior movement of the upper incisors, and the increase of maxillary posterior

Table 3 Significance of mean changes during second 6 months (T3–T2) for the rapid palatal expansion (RPE) and the activation/deactivation-rapid palatal expansion (A/D-RPE) groups (paired *t*-test) and comparison of these changes between the two groups (independent *t*-test).

Variables		RPE			A/D-RPE			<i>P</i> **
		Mean	SD	<i>P</i> *	Mean	SD	<i>P</i> *	
Maxillary skeletal and dental								
1	SNA (°)	0.37	0.88	ns	0.33	0.70	ns	ns
2	FH⊥N–A (mm)	0.00	0.85	ns	0.40	1.23	ns	ns
3	SN/ANS–PNS (°)	−0.10	0.76	ns	−0.30	1.10	ns	ns
4	N–ANS (mm)	0.87	0.74	**	1.13	0.90	***	ns
5	S–PNS (mm)	0.63	0.52	***	1.00	0.96	**	ns
6	U1/ANS–PNS (°)	0.83	2.33	ns	0.40	2.51	ns	ns
7	U1–MaxP (mm)	0.77	0.73	**	0.93	0.90	**	ns
8	U6–MaxP (mm)	0.93	0.70	***	0.40	1.04	ns	ns
9	VRL–A (mm)	0.30	0.46	ns	0.93	0.82	**	*
10	VRL–U1 (mm)	0.70	1.01	ns	0.97	0.81	**	ns
Mandibular skeletal and dental								
11	SNB (°)	0.20	0.82	ns	0.00	0.71	ns	ns
12	SN/Go–Gn (°)	0.17	0.86	ns	−0.07	1.05	ns	ns
13	S–Go (mm)	0.97	1.03	**	0.97	1.45	ns	ns
14	N–Me (mm)	1.00	0.85	**	1.50	1.87	*	ns
15	L1/MandP (°)	0.53	2.47	ns	2.13	1.94	**	ns
16	L1–MandP (mm)	0.67	0.52	***	0.73	1.05	*	ns
17	L6–MandP (mm)	0.57	0.65	*	0.43	1.39	ns	ns
18	VRL–B (mm)	0.50	0.71	ns	0.53	1.37	ns	ns
19	VRL–Pg (mm)	0.30	0.90	ns	0.73	1.13	ns	ns
20	VRL–L1 (mm)	0.80	0.70	**	1.37	1.22	**	ns
Intermaxillary								
21	ANB (°)	0.17	0.70	ns	0.33	0.75	ns	ns
22	ANS–PNS/Go–Gn (°)	0.67	1.10	ns	0.10	1.48	ns	ns
23	Overbite (mm)	0.27	0.88	ns	0.47	0.67	*	ns
24	Overjet (mm)	−0.10	1.09	ns	−0.40	1.12	ns	ns
Soft tissue								
25	Ls–E line (mm)	0.23	1.07	ns	−0.07	0.86	ns	ns
26	Li–E line (mm)	0.17	0.86	ns	0.20	0.94	ns	ns
27	Nasolabial angle (°)	−1.47	6.52	ns	2.17	6.77	ns	ns
28	VRL–Sn (mm)	0.80	0.73	**	1.83	1.67	**	*
29	VRL–Ss (A') (mm)	1.00	0.89	**	1.40	1.15	**	ns
30	VRL–Ls (mm)	1.20	1.18	**	1.37	1.53	*	ns
31	VRL–Li (mm)	0.60	1.67	ns	1.10	1.20	**	ns
32	VRL–Si (B') (mm)	0.87	1.06	*	0.47	1.64	ns	ns
33	VRL–Pg' (mm)	0.71	0.98	*	1.13	1.41	*	ns

ns, non-significant; minus sign values indicate a decrease.

*Intragroup comparison, paired *t*-test **P* < 0.016, ***P* < 0.003, ****P* < 0.0003.**Intergroup comparison, independent *t*-test **P* < 0.05, ***P* < 0.01, ****P* < 0.001.

height were significantly greater in the A/D-RPE group. The increase of ANB angle and overjet showed significant differences between the RPE and A/D-RPE groups. Furthermore, the anterior movement of Sn, Ss, and Ls points was significantly greater in the A/D-RPE group.

Skeletal and dentoalveolar changes contributing to overjet correction are given in Figure 3 for both groups. For the RPE group, the overjet correction was 92.5 per cent

skeletal and 7.5 per cent dentoalveolar, and for the A/D-RPE group 93 and 7 per cent, respectively.

Discussion

In the present study, expansion was performed to release the maxillary sutures in all patients regardless of an existing crossbite. In the RPE group, the screw was activated twice

Table 4 Significance of mean changes during 12 months (T3–T1) for the rapid palatal expansion (RPE) and the activation/deactivation-rapid palatal expansion (A/D-RPE) groups (paired *t*-test) and comparison of these changes between the two groups (independent *t*-test).

Variables		RPE			A/D-RPE			<i>P</i> **
		Mean	SD	<i>P</i> *	Mean	SD	<i>P</i> *	
Maxillary skeletal and dental								
1	SNA (°)	2.23	1.15	***	3.43	1.27	***	**
2	FH⊥N–A (mm)	1.90	1.53	***	3.00	2.15	***	ns
3	SN/ANS–PNS (°)	−0.80	1.56	ns	−1.53	1.48	**	ns
4	N–ANS (mm)	2.00	0.93	***	2.43	1.24	***	ns
5	S–PNS (mm)	2.50	1.07	***	3.57	1.66	***	*
6	U1/ANS–PNS (°)	1.57	3.35	ns	1.53	4.73	ns	ns
7	U1–MaxP (mm)	1.60	1.06	***	1.73	1.15	***	ns
8	U6–MaxP (mm)	3.90	1.50	***	3.77	1.19	***	ns
9	VRL–A (mm)	2.33	1.19	***	4.13	1.48	***	***
10	VRL–U1 (mm)	3.60	1.96	***	6.23	1.94	***	***
Mandibular skeletal and dental								
11	SNB (°)	−1.23	1.13	**	−1.60	1.12	***	ns
12	SN/Go–Gn (°)	1.87	1.78	**	2.13	2.35	**	ns
13	S–Go (mm)	2.33	1.72	***	3.33	1.53	***	ns
14	N–Me (mm)	5.07	2.15	***	6.63	2.23	***	ns
15	L1/MandP (°)	0.30	3.44	ns	0.37	3.83	ns	ns
16	L1–MandP (mm)	1.67	0.98	***	2.17	1.29	***	ns
17	L6–MandP (mm)	1.53	1.20	***	2.00	1.24	***	ns
18	VRL–B (mm)	−1.97	2.32	*	−2.50	2.71	**	ns
19	VRL–Pg (mm)	−2.27	2.43	**	−2.50	2.96	*	ns
20	VRL–L1 (mm)	−1.37	1.83	*	−0.90	2.16	ns	ns
Intermaxillary								
21	ANB (°)	3.47	1.34	***	5.03	1.53	***	**
22	ANS–PNS/Go–Gn (°)	3.03	2.01	***	3.33	2.02	***	ns
23	Overbite (mm)	−1.50	2.01	*	−1.30	2.12	ns	ns
24	Overjet (mm)	4.97	2.07	***	7.13	2.09	***	***
Soft tissue								
25	Ls–E line (mm)	2.10	2.06	**	3.43	1.80	***	ns
26	Li–E line (mm)	−0.10	1.47	ns	0.17	1.61	ns	ns
27	Nasolabial angle (°)	−0.33	7.21	ns	1.83	5.54	ns	ns
28	VRL–Sn (mm)	2.50	1.75	***	5.07	3.28	***	**
29	VRL–Ss (A') (mm)	2.73	2.04	***	5.03	2.02	***	**
30	VRL–Ls (mm)	2.83	2.09	***	4.87	2.42	***	*
31	VRL–Li (mm)	−0.73	2.12	ns	0.37	2.07	ns	ns
32	VRL–Si (B') (mm)	−1.27	2.25	ns	−1.37	2.46	ns	ns
33	VRL–Pg' (mm)	−2.23	2.10	**	−1.83	3.11	ns	ns

ns, non-significant; minus sign values indicate a decrease.

*Intragroup comparison, paired *t*-test **P* < 0.016, ***P* < 0.003, ****P* < 0.0003.**Intergroup comparison, independent *t*-test **P* < 0.05, ***P* < 0.01, ****P* < 0.001.

daily (0.20 mm per turn) for 7 days. [Alcan et al. \(2000\)](#) performed 2 mm of expansion for 1 week to release the maxillary sutures and to enhance the protraction procedure. In the absence of a posterior crossbite, the activation of the rapid palatal expander ranged from three times a week to once or twice daily for 7–10 days ([Turley, 1996](#); [Baccetti et al., 1998](#); [Ngan et al., 1998](#); [Saadia and Torres, 2000](#)). If each activation is 0.25 mm, the amount of maximum expansion would range from 0.75 to 3.5 or 5.0 mm. In the A/D-RPE group, the activation and deactivation of the screw was performed for 4 weeks, i.e. activation, deactivation, and

activation and deactivation. Screw activation or deactivation was 2.8 mm/week. This is accepted as maxillary expansion of 11.2 mm (4 × 2.8 mm) by [Liou and Tsai \(2005\)](#).

The results at T2 and T3 showed that the repetitive activation and deactivation protocol of 4 weeks with RH application resulted in more effective protraction of the maxilla than 1 week RPE with RH application. At T3, point A moved anteriorly 4.13 mm in the A/D-RPE group. This is approximately twice the amount when compared with the RPE group (2.33 mm). [Liou and Tsai \(2005\)](#) reported that maxillary advancement in the Alt-RAMEC group was two

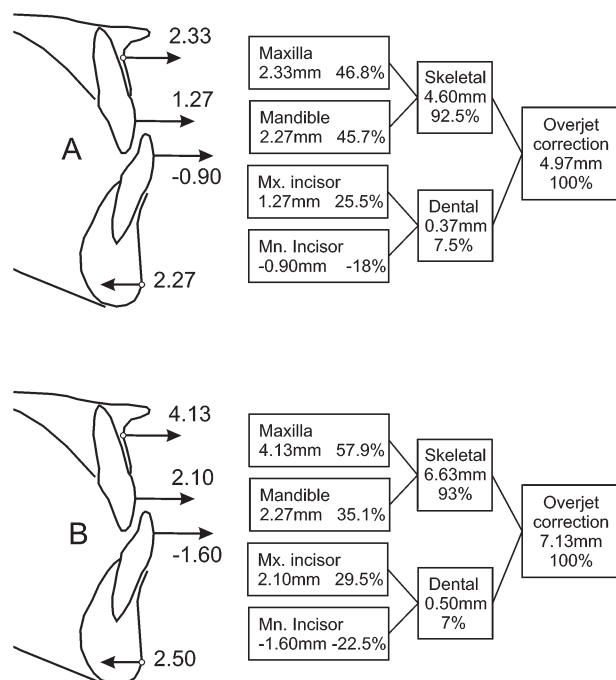


Figure 3 Skeletal and dentoalveolar changes contributing to overjet correction in the rapid palatal expansion (A) and the activation/deactivation-rapid palatal expansion (B) groups.

to three times greater than that with RPE and a facemask. This greater amount of maxillary advancement has been attributed to the expansion device (two-hinged expander), expansion protocol (Alt-RAMEC), and the intraoral protraction springs (Liou and Tsai, 2005). Liou and Tsai (2005) suggested that with Alt-RAMEC, the circum-maxillary sutures were separated and stretched to a greater degree than with RPE alone. This hypothesis was corroborated with the experimental study of Wang *et al.* (2009) who concluded that Alt-RAMEC opened the sagittally and coronally running circum-maxillary sutures quantitatively more than RPE.

Merwin *et al.* (1997) reported 2.1 mm anterior movement of point A for 9- to 12-year-old patients treated with RPE and reverse-pull headgear. Sung and Baik (1998) found 1.7 mm anterior movement of point A for a 12-year-old age group treated with RPE and a facemask. In the study by Cha (2003), anterior movement of point A was 0.97 mm for the older age group (13.07 years mean chronological age) treated with RPE and a facemask. Kapust *et al.* (1998) observed 1.97 mm anterior movement of point A for a 10–14 age group treated with RPE and a facemask. Anterior movement of point A of 2.33 mm in the RPE group in the present investigation is in agreement with the results of those studies (Merwin *et al.*, 1997; Kapust *et al.*, 1998; Sung and Baik, 1998). Nevertheless, forward movement of point A in the A/D-RPE group was more pronounced when compared with the findings of Merwin *et al.* (1997), Kapust *et al.* (1998), and Sung and Baik (1998).

Posterior rotation of the mandible and an increase of anterior face height were observed for both groups in the present study. These findings are in accordance with previous investigations (Merwin *et al.*, 1997; Kapust *et al.*, 1998; Sung and Baik, 1998; Cha, 2003). The posterior rotation of the mandible and the increase of anterior face height may be due to a combination of vertical maxillary movement, extrusion of the maxillary molars, and the chin cup effect (retraction force) of RH (Merwin *et al.*, 1997; Kapust *et al.*, 1998; Sung and Baik, 1998). In both groups, the maxillary plane angle decreased; however, a significant decrease (1.53 degrees) was observed only for the A/D-RPE group. In the studies of Merwin *et al.* (1997), Kapust *et al.* (1998), and Cha (2003), the decrease in the maxillary plane angle ranged from 0.80 to 1.46 degrees.

The increase in ANB angle showed a significant difference between the RPE and the A/D-RPE groups at T3. Posterior movement of point B and the decrease of SNB angle did not demonstrate any significant difference between the two groups, whereas the increase of SNA angle showed a significant difference. Thus, it might be stated that the pronounced increase of ANB angle originated from the greater anterior movement of point A and concomitant increase of SNA angle in the A/D-RPE group.

There was a significant difference in the correction of overjet between the two groups at T3. The greater overjet correction in the A/D-RPE group might be attributed to the greater forward movement of the maxilla and upper incisors. Even though greater anterior movement of the upper incisors in the A/D-RPE group was observed, skeletal and dental changes contributing to overjet correction were similar for both groups.

Overjet correction was achieved by 92.5 per cent skeletal and 7.5 per cent incisor tipping in the RPE group. In the A/D-RPE group, skeletal and dental contributions were 93 and 7 per cent, respectively. Maxillary skeletal contribution (57.9 per cent) was higher than mandibular skeletal contribution (35.1 per cent) to overjet correction in the A/D-RPE group, whereas, in the RPE group, the percentage of maxillary (46.8 per cent) and mandibular (45.7 per cent) contributions were almost equal. Overjet correction was primarily the result of forward movement of the maxilla and posterior rotation of the mandible in both groups. Cha (2003) reported that in the older age group, skeletal and dental contributions to overjet correction were 63.1 per cent (maxillary 24.1 per cent and mandibular 39.0 per cent) and 36.9 per cent (maxillary 30.5 per cent and mandibular 6.5 per cent), respectively. However, in that study, the mean chronological age of the older group was 13.07 years. The higher skeletal contribution observed in the present study might be explained by the age difference. In the study of Merwin *et al.* (1997), skeletal and dental contributions to overjet correction were 63 per cent (32 per cent maxilla and 31 per cent mandible) and 37 per cent (26 per cent maxilla and 11 per cent mandible), respectively, for 9- to 12-year-old patients. In the present study, significant anterior

movement of the lower incisors was observed while the position of the chin did not change between T2 and T3 in which the use of RH was reduced to 6 hours/day. Relapse of the lower incisors reduced the dental contribution to overjet correction for both groups. Nevertheless, the skeletal contribution to overjet correction was enhanced.

At T3, improvement of the soft tissue profile was observed in both groups. Anterior movement of the upper lip and posterior movements of the lower lip and soft tissue Pg point contributed to profile improvement. Skeletal and dental changes, underlying the soft tissue, lead to profile changes (Ngan *et al.*, 1996; Arman *et al.*, 2006). In the A/D-RPE group, anterior movement of the upper lip was more pronounced than in the RPE group. These pronounced soft tissue changes might be attributed to the underlying maxillary skeletal and dental changes in the A/D-RPE group.

In the present study, the first 6 months was considered the active part of treatment. In the first half of this period, RH was used for 16–18 hours/day and in the second half for 12 hours/day. The second 6 month period, RH application for 6 hours/day, was considered the passive part of treatment to retain the skeletal and dental changes. A positive overjet was obtained during the first 3–6 months. During T2–T3, the dentofacial changes, resulting in overjet and soft tissue profile correction, were maintained. No statistically significant relapses were observed. Saadia and Torres (2000) recommended 14 hours daily use of RH for children over the age of 9 years. Macdonald *et al.* (1999) and Vaughn *et al.* (2005) used RH for nighttime or bedtime to maintain treatment results after overjet correction for 3–4 or 3–6 months, respectively.

Conclusions

1. The pronounced anterior movement of point A in the A/D-RPE group demonstrated that RPE carried out with an activation–deactivation protocol positively affects maxillary protraction.
2. Skeletal contribution to overjet correction was more pronounced than dental contribution in both groups.
3. Skeletal contribution to overjet correction was primarily the result of forward movement of the maxilla and posterior rotation of the mandible in both groups.
4. Dentofacial changes, resulting in overjet and soft tissue profile correction, were maintained during the second 6 months in which the RH was worn for 6 hours/day.

References

- Alcan T, Keles A, Erverdi N 2000 The effects of a modified protraction headgear on maxilla. *American Journal of Orthodontics and Dentofacial Orthopedics* 117: 27–38
- Arman A, Ufuk Toygar T, Abuhijleh E 2006 Evaluation of maxillary protraction and fixed appliance therapy in Class III patients. *European Journal of Orthodontics* 28: 383–392
- Baccetti T, McGill J S, Franchi L, McNamara J A Jr, Tollaro I 1998 Skeletal effects of early treatment of Class III malocclusion with maxillary expansion and face-mask therapy. *American Journal of Orthodontics and Dentofacial Orthopedics* 113: 333–343
- Cha K S 2003 Skeletal changes of maxillary protraction in patients exhibiting skeletal Class III malocclusion: a comparison of three skeletal maturation groups. *Angle Orthodontist* 73: 26–35
- Dellinger E L 1973 A preliminary study of anterior maxillary displacement. *American Journal of Orthodontics* 63: 509–516
- Ellis E III, McNamara J A Jr 1984 Components of adult Class III malocclusion. *Journal of Oral and Maxillofacial Surgery* 42: 295–305
- Göyenc Y, Ersoy S 2004 The effect of a modified reverse headgear force applied with a facebow on the dentofacial structures. *European Journal of Orthodontics* 26: 51–57
- Guyer E C, Ellis E E III, McNamara J A Jr, Behrens R G 1986 Components of Class III malocclusion in juveniles and adolescents. *Angle Orthodontist* 56: 7–30
- Jacobson A, Evans W G, Preston C B, Sadowsky P L 1974 Mandibular prognathism. *American Journal of Orthodontics* 66: 140–171
- Kajiyama K, Murakami T, Suzuki A 2004 Comparison of orthodontic and orthopedic effects of a modified maxillary protractor between deciduous and early mixed dentitions. *American Journal of Orthodontics and Dentofacial Orthopedics* 126: 23–32
- Kapust A J, Sinclair P M, Turley P K 1998 Cephalometric effects of face mask/expansion therapy in Class III children: a comparison of three age groups. *American Journal of Orthodontics and Dentofacial Orthopedics* 113: 204–212
- Kiliçoglu H, Kiriç Y 1998 Profile changes in patients with Class III malocclusions after Delaire mask therapy. *American Journal of Orthodontics and Dentofacial Orthopedics* 113: 453–462
- Liou E J 2005a Toothborne orthopedic maxillary protraction in Class III patients. *Journal of Clinical Orthodontics* 39: 68–75
- Liou E J 2005b Effective maxillary orthopedic protraction for growing Class III patients: a clinical application simulates distraction osteogenesis. *Progress in Orthodontics* 6: 154–171
- Liou E J, Tsai W C 2005 A new protocol for maxillary protraction in cleft patients: repetitive weekly protocol of alternate rapid maxillary expansions and constrictions. *Cleft Palate-Craniofacial Journal* 42: 121–127
- Macdonald K E, Kapust A J, Turley P K 1999 Cephalometric changes after the correction of Class III malocclusion with maxillary expansion/facemask therapy. *American Journal of Orthodontics and Dentofacial Orthopedics* 116: 13–24
- McNamara Jr J A, Brudon W L 1993 *Orthodontic and orthopedic treatment in the mixed dentition*. Needham Press, Ann Arbor
- Mermigios J, Full C A, Andreasen G 1990 Protraction of the maxillofacial complex. *American Journal of Orthodontics and Dentofacial Orthopedics* 98: 47–55
- Merwin D, Ngan P, Hägg U, Yiu C, Wei S H 1997 Timing for effective application of anteriorly directed orthopedic force to the maxilla. *American Journal of Orthodontics and Dentofacial Orthopedics* 112: 292–299
- Ngan P, Hägg U, Yiu C, Merwin D, Wei S H 1996 Soft tissue and dentoskeletal profile changes associated with maxillary expansion and protraction headgear treatment. *American Journal of Orthodontics and Dentofacial Orthopedics* 109: 38–49
- Ngan P, Yiu C, Hu A, Hägg U, Wei S H, Gunel E 1998 Cephalometric and occlusal changes following maxillary expansion and protraction. *European Journal of Orthodontics* 20: 237–254
- Saadia M, Torres E 2000 Sagittal changes after maxillary protraction with expansion in Class III patients in the primary, mixed, and late mixed dentitions: a longitudinal retrospective study. *American Journal of Orthodontics and Dentofacial Orthopedics* 117: 669–680
- Sanborn R T 1955 Differences between the facial skeletal patterns of Class III malocclusion and normal occlusion. *Angle Orthodontist* 25: 208–222
- Suda N, Ishii-Suzuki M, Hirose K, Hiyama S, Suzuki S, Kuroda T 2000 Effective treatment plan for maxillary protraction: is the bone age useful

- to determine the treatment plan? *American Journal of Orthodontics and Dentofacial Orthopedics* 118: 55–62
- Sung S J, Baik H S 1998 Assessment of skeletal and dental changes by maxillary protraction. *American Journal of Orthodontics and Dentofacial Orthopedics* 114: 492–502
- Turley P K 1996 Orthopedic correction of Class III malocclusion: retention and phase II therapy. *Journal of Clinical Orthodontics* 30: 313–324
- Turley P K 2007 Treatment of the Class III malocclusion with maxillary expansion and protraction. *Seminars in Orthodontics* 13: 143–157
- Vaughn G A, Mason B, Moon H B, Turley P K 2005 The effects of maxillary protraction therapy with or without rapid palatal expansion: a prospective, randomized clinical trial. *American Journal of Orthodontics and Dentofacial Orthopedics* 128: 299–309
- Wang Y C, Chang P M, Liou E J 2009 Opening of circumaxillary sutures by alternate rapid maxillary expansions and constrictions. *Angle Orthodontist* 79: 230–234
- Williams S, Andersen C E 1986 The morphology of the potential Class III skeletal pattern in the growing child. *American Journal of Orthodontics* 89: 302–311